

# RECONSTRUCTION OF RETINAL VASCULAR TREE IN OPTICAL COHERENT TOMOGRAPHY

**Pavλίna Macková**

Doctoral Degree Programme (1), DBME FEEC BUT

E-mail: xmacko03@stud.feec.vutbr.cz

Supervised by: Radim Kolář

E-mail: kolarr@feec.vutbr.cz

**Abstract:** In this paper the reconstruction of retinal vascular tree from three dimensional spectral optical coherent tomography (3D OCT) is described. For reconstruction the three different types of reconstruction and four types of 2D projection from 3D OCT scans are used. The results are compared with image obtained from scanning laser ophthalmoscope (SLO).

**Keywords:** optical coherence tomography, scanning laser ophthalmoscope, reconstruction, retina, blood vessel, B-scan, A-scan, 2D projection

## 1. INTRODUCTION

Optical coherence tomography (OCT) is non-invasive and non-contact diagnostic tool used in different application field. One of the most developing applications is ophthalmology. The OCT technique uses low coherence infrared light to obtain 2D images similar to ultrasound imaging. Thus the OCT technique provides cross-sectional retinal images and is used for diagnosis of a variety of retinal diseases like diabetic retinopathy, glaucoma or age related macular degeneration. The spectral domain optical coherent tomography (SD-OCT) is an advanced modification older time domain OCT. The SD-OCT has higher resolution, sensitivity and recording speed and also allows reduction of motion artifacts. This allows more accurate analysis of the retinal structures, retinal layers, blood vessels, early detection and monitoring the progression of eye diseases. [2] [9]

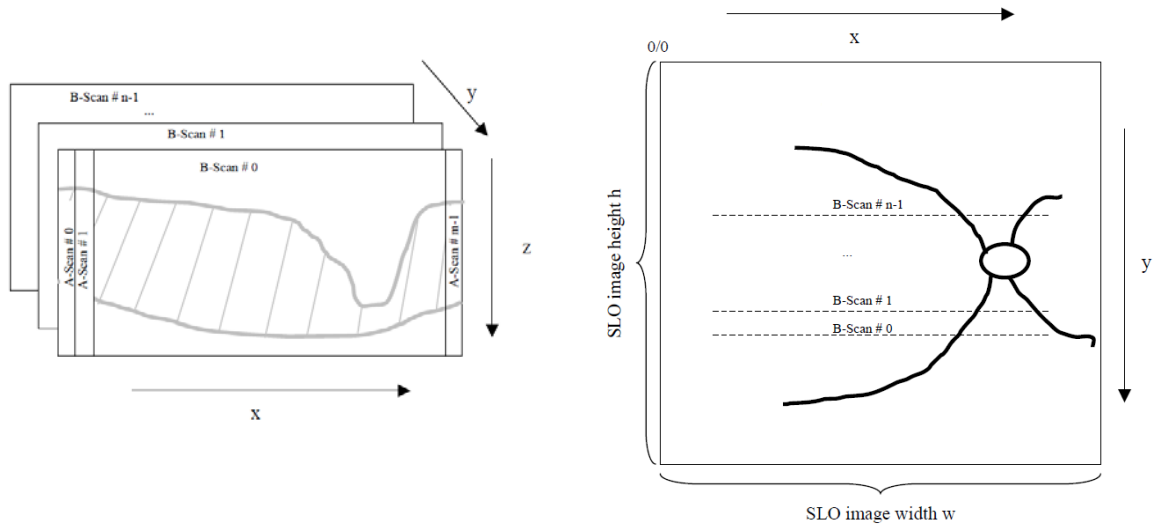
A 3D blood vessel segmentation is a challenging problem, which has not been fully resolved. The first blood vessel segmentation method based on 3D spectral OCT images was presented by Niemeijer at al. [5]. This method uses 2D projection image of the vessel and pixel classification based vessel segmentation approach. A similar classification based segmentation approach using 2D projection was proposed by Xu at al. [9]. Compared to the previous, this method does not rely on retinal layer segmentation. Xu at al. used training algorithm to identify automatically blood vessel and applied trained algorithm for automated vessel identification/classification.

This paper describes a method for reconstruction of the blood vessel tree from 3D volume OCT data. It is based on 2D projection method which was used by Niemeijer at al. [5] and Xu at al. [9]. This method is prerequisite step for 3D segmentation and is utilized to define a position of the retinal blood vessels in OCT scans. It is also possible to use this reconstruction in fusion of OCT scans with images obtained from fundus camera [3].

## 2. DATA

### 2.1. 3D SD-OCT IMAGING

A 3D OCT retinal image set consists of  $n$  cross-sectional scans in  $x$ - $z$  plane (B-scans). Each B-scan is composed of  $m$  scans in  $z$  direction (A-scans). See Figure 1(left) for coordinate system, which is usually used on OCT field.



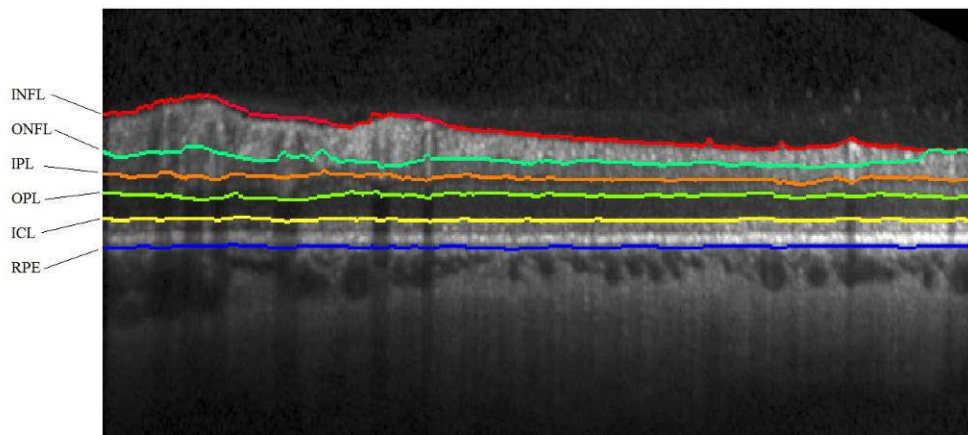
**Figure 1:** Coordinate system of OCT scans (left) and SLO imaging (right) [7]

The OCT devices (e.g. Spectralis, RTVue, Stratus) usually employ a scanning laser ophthalmoscope (SLO) for fast retinal scanning, which allows imaging of retina and blood vessels with a high sensitivity.[8] This method is helpful in diagnosis of macular degeneration or glaucoma and can be also used as a standalone imaging technique. The coordinate system of SLO image is shown in Figure 1(right). The SLO image will be used only in evaluation part (Section 4).

## 2.2. RETINAL LAYER SEGMENTATION

The direct representation of retinal blood vessels is not possible due to absorption of wavelengths used in spectral OCT. But OCT image contains silhouettes that appear below the position of the vessels and indicate location of retinal blood vessels. This knowledge about position of vessel silhouettes in the outer retinal layers is used for vessel segmentation approaches. [5]

The main retinal layers are depicted in Figure 2. These are: nerve fibre layer (NFL), inner plexiform layer (IPL), inner nuclear layer (INL), outer plexiform layer (OPL), outer nuclear layer (ONL) and photoreceptor outer segments (POS). [1] Moreover is possible to find inner nerve fibre layer (INFL), outer nerve fibre layer (ONFL), inner collagenous layer (ICL) and retina pigment epithelium (RPE). Example of retinal layer segmentation with software OCTSEG [4] is shown in Figure 2.

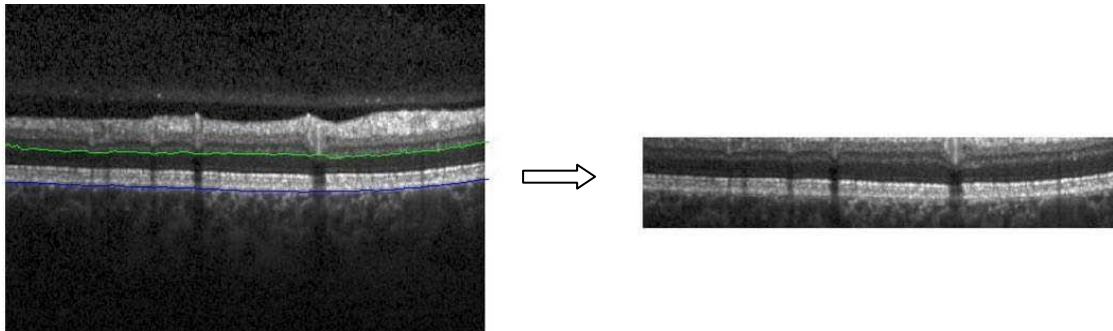


**Figure 2:** Segmented retinal layers RPE, ICL, OPL, IPL, ONFL and INFL (from bottom)

### 3. METHODS

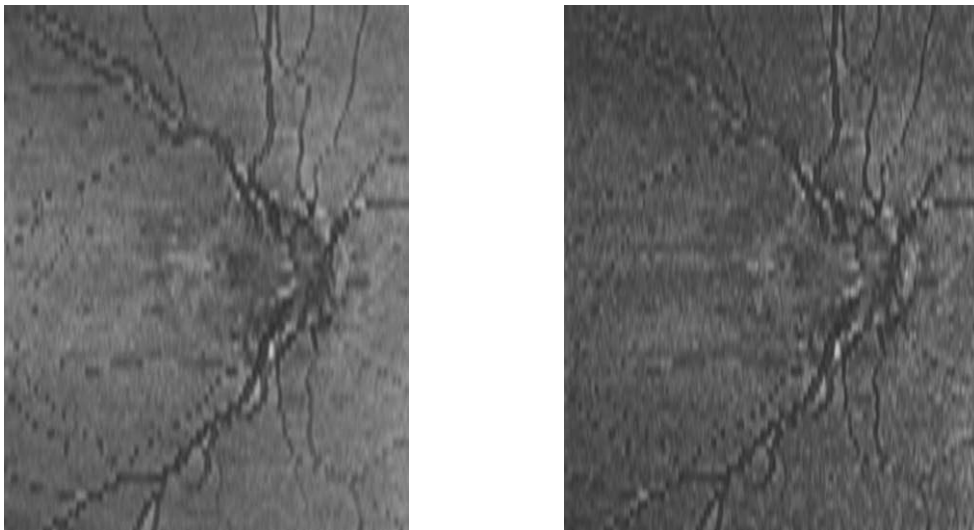
The first step of blood vessel reconstruction is to segment specific retinal layer. For this purpose the software OCTSEG [4] is used, which allows segmentation of different retinal layers in OCT scans.

For the blood vessel reconstruction the layer OPL and RPE were segmented in each B-scans (green and blue line in Figure 2 and Figure 3, left). Segmentation of the other layers is not required, because area between OPL and RPE layers definitely contains blood vessels' silhouettes. The final region of interest (ROI) from the original B-scan is defined by the minimal z coordinate of RPE layer and maximal z coordinate of OPL value (Figure 3, right).

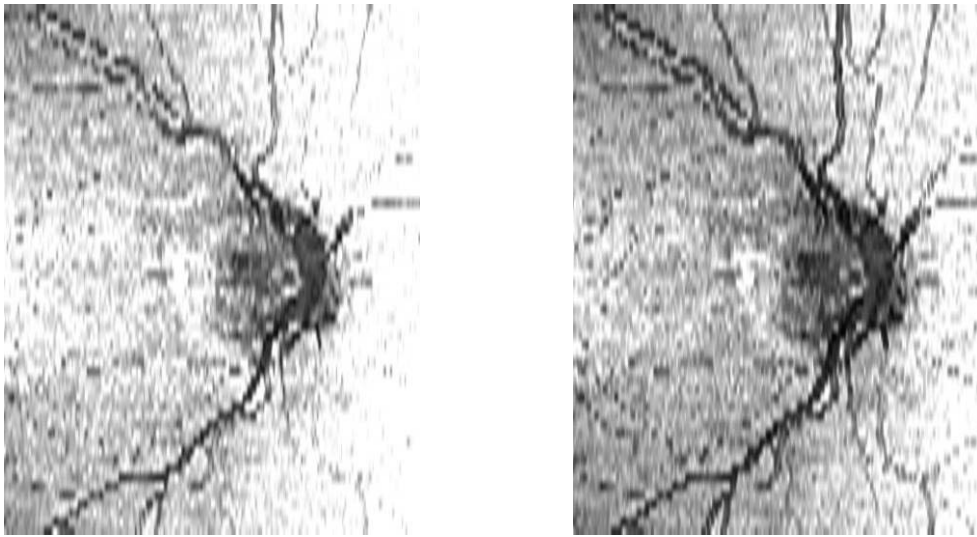


**Figure 3:** Segmented retina layer OPL and RPE (left) and final region of interest of the original B-scan (right)

The whole 3D ROI is then used for 2D projection. There were used four types of 2D projection for three different types of reconstruction approaches. The first projection is composed by averaging (mean) A-scan crossing ROI, for the second projection median is used and last two projections are made by finding maximum and minimum from each A-scan crossing ROI. The first reconstruction is constructed from z-directions for every three neighboring x locations (three A-scans) and every y locations (reconstruction “A”). The second reconstruction is moreover made by three neighboring y locations (reconstruction “B”). And the last reconstruction is constructed from z-direction for every x locations and three neighboring y locations (reconstruction “C”). Example of different projection results using reconstruction A shows Figure 4 and Figure 5.



**Figure 4:** Reconstruction type “A” with 2D projection by mean (left) and median (right)



**Figure 5:** Reconstruction type “A” with 2D projection by maximum (left) and minimum (right)

#### 4. RESULTS AND DISCUSSION

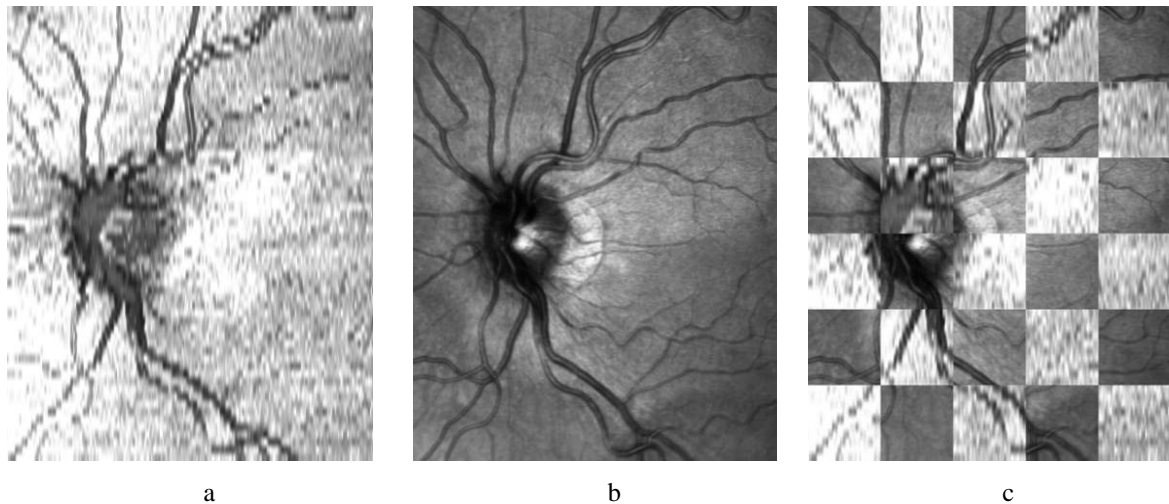
The result of different blood vessel reconstruction methods was evaluated on the basis of deviation over blood vessels. The results were obtained by evaluation of 5 data sets. For evaluation the 2D projection created from minimal value was selected. This was selected based on the comparison of histograms from each projections.

The results of all types of 2D projections were compared with corresponding SLO image using position of each B-scan provided by Spectralis machine (2D projection and SLO, Figure 6). The software, which evaluates deviations over vessels at the borderline of compared images, was used. This software is semiautomatic - the user selects areas for evaluation and the calculation is done automatically. [6]

The Table 1 shows that the best reconstruction from OCT scans is in reconstruction “A”. Also the best subjective evaluation belongs to projection “A”. The deviation over vessels in average for projection “A” is 5,83 pixels. For all projections the deviation is 7,584 pixels in average. The evaluation of deviation was following: to 4 pixels – perfect, form 4 to 8 pixels – good, from 8 to 12 pixels acceptable and up to 12 pixels insufficient.

	Deviation over vessels in average [pixel]		
	Reconstruction type “A”	Reconstruction type “B”	Reconstruction type “C”
<b>Data 1</b>	7,43	7,07	8,09
<b>Data 2</b>	5,00	7,48	7,37
<b>Data 3</b>	7,05	9,50	8,98
<b>Data 4</b>	5,30	7,88	7,75
<b>Data 5</b>	4,35	10,01	10,50

**Table 1:** Deviation over vessels in average



**Figure 6:** The result of reconstruction type “A” from 2D projection obtained by minimal values (a) and corresponding SLO image (b) and comparison of these images (c)

#### ACKNOWLEDGEMENT

This work has been supported by Czech-German project no. 7AMB12DE002 under Ministry of Education, Youth and Sports.

#### REFERENCES

- [1] Bagci, A.M.; Ansari, R.; Shahidi, M.; , "A method for detection of retinal layers by optical coherence tomography image segmentation," *Life Science Systems and Applications Workshop, 2007. LISA 2007. IEEE/NIH* , vol., no., pp.144-147, 8-9 Nov. 2007
- [2] Datta, R.; Aditya, S.; Tibrewala, D.N.; , "Advancement in OCT and image-processing techniques for automated ophthalmic diagnosis," *Students' Technology Symposium (TechSym), 2010 IEEE* , vol., no., pp.26-33, 3-4 April 2010
- [3] KOLÁŘ, R.; TAŠEVSKÝ, P. Registration of 3D Retinal Optical Coherence Tomography Data and 2D Fundus Images. In *Biomedical Image registration. Lecture Notes in Computer Science*. 2010. s. 72-82. ISSN: 0302- 9743.
- [4] Mayer M., *OCTSEG*, Pattern recognition lab, University of Erlangen-Nuremberg, Germany, Release of v0.34 in July 2012.
- [5] Niemeijer M. at all, "Vessel segmentation in 3D spectral OCT scans of the retina," *Proc. SPIE* 6914, 6914R, 6914R-8 (2008)
- [6] Podlípna, P. "Multimodální registrace obrazů sítnice." Brno: Vysoké učení technické v Brně, Fakulta elektrotechniky a komunikačních technologií, 2011. 46 s. Vedoucí diplomové práce Ing. Vratislav Harabiš.
- [7] SPECTRALIS, Spectralis Viewing Module, Document revision 3.2-1E, June 2008, © Heidelberg Engineering GmbH 2008, Germany, Art. No. 97 175-001
- [8] Webb, R. H.; Hughes, G. W.; , "Scanning Laser Ophthalmoscope," *Biomedical Engineering, IEEE Transactions on* , vol.BME-28, no.7, pp.488-492, July 1981
- [9] Xu J. at all, "Blood vessel segmentation with three-dimensional spectral domain optical coherence tomography," International Patent no. WO/2010/126845 (Feb.12, 2010)